

Table 1 Clinical characteristics of all reports of malignant hypertension with diffuse alveolar haemorrhage.

Case	Age	Gender	Nationality	Smoking	Previous HT	Family history of HT	Air travel	Ref.
1	34	Male	Japanese	NR	1 month	NR	NR	1
2	26	Male	North American	1–2 cig./day	No	Both parents	Yes	5
3	26	Male	Japanese	NR	3 years	NR	Yes	3
4	38	Male	Canadian	9 packs-year	3 months	NR	NR	4
5	32	Male	Japanese	NR	5 years	Both parents	NR	6
6	27	Male	Japanese	>30 pack-year	No	NR	NR	2
7	51	Male	Portuguese	>30 pack-year	No	Mother	No	–

HT: systemic hypertension; cig.: cigarette; NR: no reference; Ref.: reference.

However, it is worth noting that no other findings have supported this hypothesis, and this may be just a non-significant association. In conclusion, our and previous reports of malignant hypertension associated DAH suggest that high blood pressure may be a significant cause of alveolar haemorrhage. Clinicians caring for DAH patients should be aware of this association. We also propose large-scale studies on the association between systemic blood pressure and the risk of alveolar haemorrhage which could open the way to new treatment of DAH with BP lowering agent.

Disclosure

The authors report no financial support, off-label or investigational drug use.

Conflicts of interest

The authors have no conflicts of interest to declare.

References

- Hida K, Wada J, Odawara M, Kunitomi M, Hayakawa N, Kashihara N, et al. Malignant hypertension with a rare complication of pulmonary alveolar hemorrhage. *Am J Nephrol.* 2000;20:64–7.
- Park HS, Hong YA, Chung BH, Kim HW, Park CW, Yang CW, et al. Malignant hypertension with an unusual presentation mimicking the immune mediated pulmonary renal syndrome. *Yonsei Med J.* 2012;53:1224–7.

- Sato Y, Hara S, Yamada K, Fujimoto S. A rare case of alveolar haemorrhage due to malignant hypertension. *Nephrol Dial Transplant.* 2005;20:2289–90.
- Aithal S, Marley N, Venkat-Raman G. An unusual non-immunological cause of renal pulmonary syndrome. *Clin Nephrol J.* 2009;72:322–5.
- Dalal P, Phadke G, Gill A, Tarwater K, Misra M, Pele N, et al. Case report – A patient with hemoptysis and renal failure. *Int J Hypertens.* 2011;2011:1–3.
- Nanba K, Yahata K, Kikuchi Y, Okamoto C, Seta K, Sugawara A. A rare case of malignant-phase hypertension with pulmonary alveolar hemorrhage. *Clin Exp Nephrol.* 2011;15:303–7.

Joana Clemente Duarte^{a,*}, Rita Leal^b, Luís Escada^b, Tiago M. Alfaro^a

^a *Pneumology Unit A, Centro Hospitalar e Universitário de Coimbra, Coimbra, Portugal*

^b *Nephrology Unit, Centro Hospitalar e Universitário de Coimbra, Coimbra, Portugal*

* Corresponding author.

E-mail address: Joana_Duarte_17@hotmail.com (J.C. Duarte).

<http://dx.doi.org/10.1016/j.rppnen.2016.10.002>
2173-5115/

© 2016 Sociedade Portuguesa de Pneumologia. Published by Elsevier España, S.L.U. This is an open access article under the CC BY-NC-ND license (<http://creativecommons.org/licenses/by-nc-nd/4.0/>).

Mesothelial cyst of the pulmonary ligament: An uncommon lesion



Dear Editor,

The importance of a thorough knowledge of thoracic anatomy is timeless. Lung and pleural anatomy continues to be a subject for study nowadays, not only due to the greater spatial resolution of newer diagnostic studies, such as bronchoscopy, computed tomography and magnetic resonance, but also because of advances in thoracic surgery.

The pulmonary ligaments are among the lesser known structures of the thoracic anatomy. The radiological importance of the pulmonary ligament was first described in

1966 by Rabinowitz and Wolfe,¹ and only very few reports or series have been found which describe the radiological findings of pathologic processes within the pulmonary ligaments.^{1–6} This ligament, just like any other thoracic anatomical structure can be affected by non-infectious or infectious inflammatory processes, tumors, congenital or developmental abnormalities and scarring.^{2–6} There are only a few reports in the literature which mention this anatomical structure and different pathological process.

The following case description of a cystic lesion within the right pulmonary ligament illustrates the anatomy and pathology of this structure:

A 75-year-old woman diagnosed with a pharyngeal cancer was referred for magnetic resonance imaging of the neck and a computed tomography (CT) of the chest and

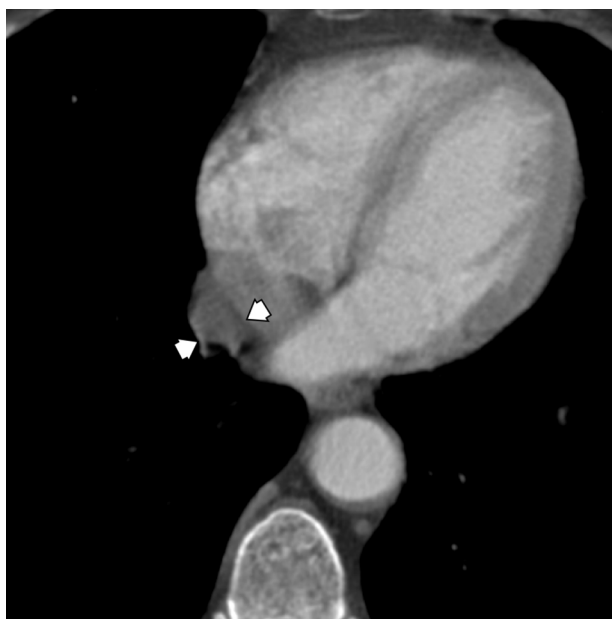


Figure 1 CT shows a cyst within the pulmonary ligament separated by fat plane from the pericardium.

upper abdomen. The enhanced CT chest demonstrated an incidental tubular cystic lesion, oriented parallel to the mediastinum, within the right pulmonary ligament, extending from the level just caudal to the right inferior pulmonary vein down to the diaphragm. This lesion measured 5.5 cm × 2.7 cm × 1.8 cm and showed homogeneous density, mean attenuation value = -3.92 Hounsfield Units (HU). This lesion was separated from pericardium by a layer of fat. The lesion was followed up and remained stable in size and shape for 4 years, as per the comparison with a previous CT scan. The appearance on axial, coronal and sagittal planes confirmed that the cyst was within the pulmonary ligament (Figs. 1 and 2). The cystic lesion also had no depression of the hilar structures or elevation or blurring of the diaphragm. So the non-symptomatic clinical setting alongside with the anatomical landmarks described and the lack of change in size/configuration during these years supported the diagnosis of a mesothelial cyst of the pulmonary ligament.

This case under discussion provides a very good illustration of the anatomical concepts that define the pulmonary ligament as double layer of pleura that drapes caudally from the lung root and ropes the medial aspect of the lower lobes of the lung to the mediastinum.² On the left, the ligament is medial and adjacent to the esophagus and is bounded posteriorly by the descending aorta. On the right, the ligament is posterior to the inferior vena cava and anterior to the azygos vein.²⁻⁴ Each ligament contains connective tissue which blends with the hilar connective tissue superiorly, and with mediastinal connective tissue medially. Laterally, the connective tissue of the ligaments is continuous with the interstitial connective tissue of the lung.²⁻⁴

On CT scans normal ligament can be visible as a thin linear density arising from the mediastinum below the hilar structures on lung window.³

Few reports in the literature have described air within the pulmonary ligament, post-traumatic or from ruptured

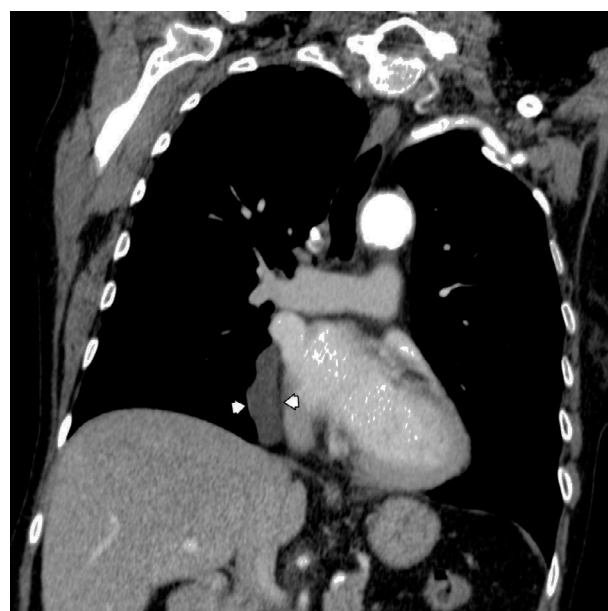

Figure 2 CT sagittal view shows the tubular cystic lesion laterally to the inferior vena cava, extending from the level of the right inferior pulmonary vein to the diaphragm.

pneumatocoles in neonates under mechanical ventilation.⁴⁻⁶ Moreover, around 11–18% of mediastinal masses are related to the foregut developmental abnormalities, including bronchogenic or duplication cysts. The phase of the embryonic development during which the error occurs seems to play a role in the location and type of malformation. Foregut cysts arise late in the gestation. The age of presentation may vary from prenatal to late adulthood. Almost a quarter of the patients with foregut cysts are asymptomatic.⁷ The presented clinical case therefore illustrates a rare but typical cystic lesion, probable arising from developmental error within the pulmonary ligament.

Funding

All authors declare that no funding was provided for this case report.

Conflicts of interest

The authors have no conflicts of interest to declare.

References

1. Rabinowitz JG, Wolf BS. Roentgen significance of the pulmonary ligament. *Radiology*. 1966;87:1013–20.
2. Mintzer RA, Hendrix RW, Johnson CS, Neiman HL, Cugell DW. The radiologic significance of the left pulmonary ligament. Experience with 26 patients. *Chest*. 1979;76:401–5.
3. Cooper C, Moss AA, Buy JN, Stark DD. CT appearance of the normal inferior pulmonary ligament. *AJR*. 1983;141:237–40.
4. Volberg FM Jr, Everett CJ, Brill PW. Radiologic features of inferior pulmonary ligament air. Collections in neonates with respiratory distress. *Radiology*. 1979;130:357–60.

5. Friedman PJ. Adult pulmonary ligament pneumatocele: a loculated pneumothorax. *Radiology*. 1985;155:575–6.
6. Ravin CE, Smith GW, Lester PD, McLoud TC, Putman CE. Post-traumatic pneumatocele in the inferior pulmonary ligament. *Radiology*. 1976;121:39–41.
7. Meza MP, Benson M, Slovis TL. Imaging of mediastinal masses in children. *Radiol Clin N Am*. 1993;31:583–604.

D. Penha^a, E.G. Pinto^{b,*}, E. Marchiori^c, A. Costa^a,
W.E. Neto^d, K.L. Irion^e

^a *Radiology Department, Hospital Prof. Dr. Fernando Fonseca, Lisbon, Portugal*

^b *Radiology Department, Lincoln County Hospital, Lincoln, United Kingdom*

^c *Radiology Department, The Federal University of Rio de Janeiro, Rio de Janeiro, Brazil*

^d *Radiology Department, The Federal University of Rio Grande do Sul, Porto Alegre, Brazil*

^e *Radiology Department, Liverpool Heart and Chest Hospital, Liverpool, United Kingdom*

* Corresponding author.

E-mail address: ericguedespinto@gmail.com (E.G. Pinto).

<http://dx.doi.org/10.1016/j.rppnen.2016.10.003>
2173-5115/

© 2016 Sociedade Portuguesa de Pneumologia. Published by Elsevier España, S.L.U. This is an open access article under the CC BY-NC-ND license (<http://creativecommons.org/licenses/by-nc-nd/4.0/>).

High-flow nasal oxygen is not an oxygen therapy device



Traditionally the oxygen therapy systems have been classified as low and high flow. Low-flow systems do not provide all the inspiratory flow demanded by the patient; do not ensure stable levels of FiO₂ and it is not possible to control the temperature and moisture of inspired gas. The low flow oxygen system most widely used is the nasal prongs. By contrast, high flow systems are able to provide the entire atmosphere breathed by the patient and do ensure a stable FiO₂ and it is possible to control the temperature and moisture of the inspired gas. The typical high flow oxygen system is the venturi mask.¹ In recent years, a new way of supplying patients with oxygen has appeared which in our opinion has been incorrectly called high-flow nasal cannula oxygen therapy (HFNC).² This therapeutic approach has a lot of physiological effects which makes it a really active treatment for patients with both acute and chronic respiratory failure; it is more than a simple oxygen delivery system. Several studies have shown that HFNC generates a low level of positive airway pressure, improves oxygenation, increases the end-expiratory lung volume, reduces airway resistance, increases functional residual capacity and alveolar recruitment and flushes nasopharyngeal dead space, thus helping to decrease the work of breathing. There is a better control of FiO₂ and the gas humidification ensures better patient tolerance and comfort. Due to a better mucociliary clearance, pulmonary defense mechanisms are restored.³ Many of these effects are similar to those produced by non-invasive ventilation. Several studies have shown its utility in patients with acute hypoxemic respiratory failure, in the post-extubation period, in palliative care, in patients with acute heart failure, in chronic airway diseases and its indications are still rising. It is used in critical care areas, in the emergency department, in wards and it is being used at home in COPD patients.^{4,5}

As we can see, oxygen plays a secondary role in this treatment. The name of high-flow oxygen therapy is confusing. Although the efficacy of improvement in respiratory gas exchange and effectiveness in outcomes has been demonstrated, we have not fully understood the main pathophysiological principles of this therapy. The role and importance of each of the mechanisms related to the

high-flow therapy, the end expiratory positive pressure, the flushing of nasopharyngeal dead space or the humidification and warming of the inspired air, has not been clarified yet. Up to now, we have not been able to identify the functional significance of each of the three mechanisms, maybe this is a question that will never be answered because in different clinical situations the relevance of these potential mechanisms changes. What is clear is that high-flow is not an oxygen therapy device. Most international groups working in this field use the term ‘‘Nasal High Flow’’ avoiding the term ‘‘oxygen’’ in its definition.

We think such an active treatment should have a name that reflects the effects of the treatment better, in order to avoid confusion. And that deserves some careful reflection. High-flow can be applied through nasal cannula or tracheostomy, so the term ‘‘nasal’’ should not be part of the name. Perhaps the name ‘‘Active High Flow’’ would be more accurate so as to clearly distinguish it from the conventional or ‘‘passive’’ high flow like the venturi system. The Venturi system is usually administered by mask and high flow by cannula, which could be another distinguishing feature. Taking into account the different but also relevant effects of the therapy, we might ask why not include the term ‘‘humidification’’ or ‘‘heating’’ to the words ‘‘high flow’’. The positive expiratory pressure effect could probably be more interesting to incorporate into the name. Although the pressure achieved is highly dependent on the individual patient and the interface used, is low in absolute value and, above all, not determined by the prescribed parameters of the equipment, we do have quite a lot about its relevance. Certainly, this therapy has demonstrated that can be useful in treating sleep apnea syndrome.^{6,7} Its effect on alveolar recruitment has been clearly shown by Corley et al.⁸ Roca et al.⁹ have also indirectly demonstrated the positive intrathoracic pressure reached with the HFNC, showing a reduction greater than 20% in the estimated inspiratory collapse of the inferior vena cava from baseline. Perhaps the provocative name of ‘‘High-flow positive pressure’’ would better define a treatment that gives the patient a high flow of heated and wet gas, with a level of positive pressure, and a controlled FiO₂. Anyway, the name of high-flow oxygen therapy would be restricted to the classical high flow system such as the venturi system. We think that a consensus on a more precise name is required.