



IMAGE IN CARDIOLOGY

Right ventricular perforation as a complication of fluoroscopy-guided pericardiocentesis

Perfuração ventricular direita como complicação de pericardiocentese guiada por fluoroscopia

Mehrnoush Toufan^a, Leili Pourafkari^{a,b}, Nader D. Nader^{b,*}



^a Tabriz University of Medical Sciences, Tabriz, Iran

^b Department of Anesthesiology, University at Buffalo, Main Campus, State University of New York at Buffalo, Buffalo, USA

Received 4 May 2016; accepted 12 May 2016

Available online 31 May 2017

A 77-year-old woman presented to our emergency department with worsening shortness of breath. She was hemodynamically stable. Initial work-up was significant for hemoglobin 10.3 g/dl and enlarged cardiac silhouette on the chest X-ray. Transthoracic echocardiography showed a large circumferential pericardial effusion and dilated inferior vena cava. There was no right chamber collapse. Therapeutic pericardiocentesis was performed in the cardiac catheterization laboratory. An attempt was made to drain the pericardial fluid through a subxiphoid window under fluoroscopic guidance using a percutaneous needle. About 200 ml of serosanguinous fluid was aspirated. A guide wire was then advanced through the needle hub, the needle was removed and a pigtail catheter was introduced and left in place through a catheter-over-wire technique for further drainage. The procedure was considered successful by the performing cardiologist and the patient was admitted. No further drainage was noticed during the next 12 hours. The

patient remained stable but did not report any improvement in her symptoms. Follow-up echocardiography 12 hours after the procedure showed massive pericardial effusion with dilated inferior vena cava. The catheter was seen in the right ventricle passing through the right ventricular free wall (Figures 1 and 2). Intravenous injection of agitated saline showed the catheter had advanced to the main pulmonary artery (Figure 3, Videos 1-3). Inadvertent right ventricular perforation and advancement of the pigtail catheter to the pulmonary artery was diagnosed and the patient required surgery for removal of the catheter and repair of the right ventricular free wall.

The case highlights a potentially serious complication of fluoroscopy-guided pericardiocentesis. Echocardiography-guided pericardiocentesis is shown to be safe and effective, and is the technique of choice for draining pericardial effusions. Additionally, initial drainage should be done through the catheter using an over-the-wire technique rather than needle aspiration, which should be reserved for emergent situations and limited access to imaging modalities.

* Corresponding author.

E-mail address: nnader@buffalo.edu (N.D. Nader).

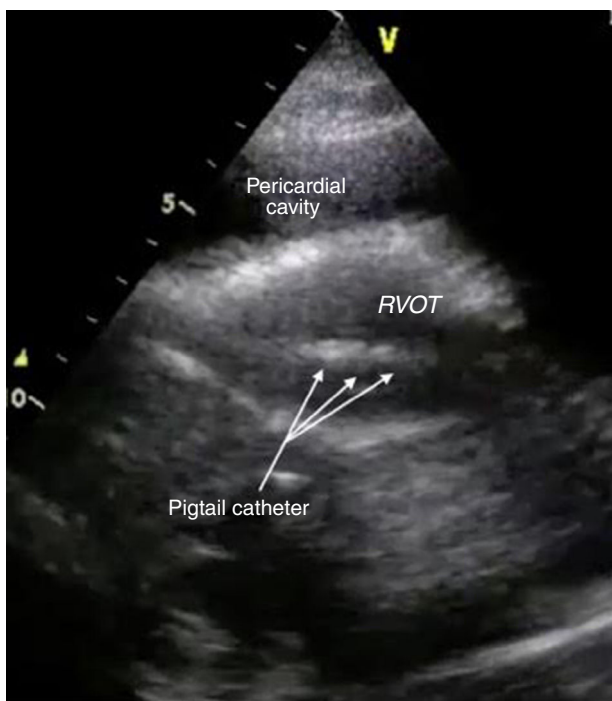


Figure 1 Long-axis parasternal transthoracic echocardiographic view showing the pigtail catheter in the right ventricle. RVOT: right ventricular outflow tract.

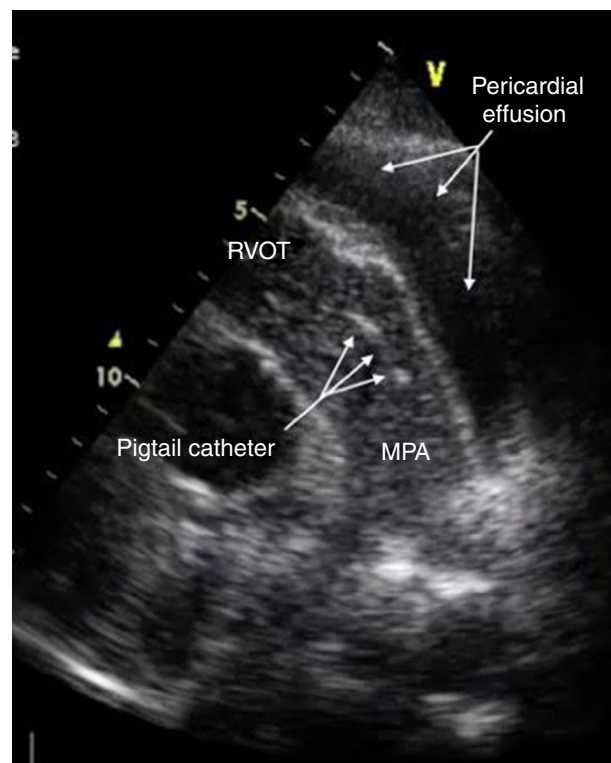


Figure 3 Contrast injection in parasternal short-axis echocardiographic view showing the catheter in the main pulmonary artery. MPA: main pulmonary artery; RVOT: right ventricular outflow tract.

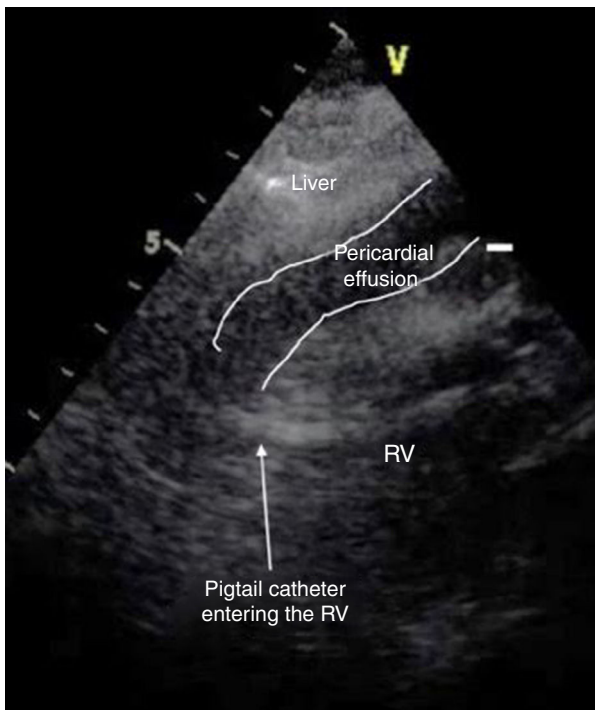


Figure 2 Subxiphoid transthoracic echocardiography showing a large pericardial effusion and the catheter passing through the right ventricular wall. RV: right ventricle.

Ethical disclosures

Protection of human and animal subjects. The authors declare that no experiments were performed on humans or animals for this study.

Confidentiality of data. The authors declare that no patient data appear in this article.

Right to privacy and informed consent. The authors declare that no patient data appear in this article.

Conflicts of interest

The authors have no conflicts of interest to declare.

Appendix A. Supplementary material

Supplementary material associated with this article can be found in the online version at [doi:10.1016/j.repc.2016.05.013](https://doi.org/10.1016/j.repc.2016.05.013).