



IMAGE IN CARDIOLOGY

Early restrictive-constrictive physiology in a cardiac allograft recipient



Fisiologia restritiva-constritiva em recetor de aloenxerto cardíaco

Carlos Ortiz-Bautista*, Elena Puerto García-Martín, Laura Morán-Fernández, Inés Ponz-de Antonio, Adriana Rodríguez-Chaverri, Juan F. Delgado-Jiménez

Unidad de Insuficiencia Cardíaca, Trasplante e Hipertensión Pulmonar, Servicio de Cardiología, Hospital Universitario 12 de Octubre, Madrid, Spain

Received 13 July 2016; accepted 26 July 2016

Available online 5 July 2017

A 57-year-old man with personal history of dilated ischemic cardiomyopathy and advanced heart failure was referred to our unit for cardiac transplantation evaluation. After ruling out contraindications, elective cardiac transplantation

was performed without postoperative complications. The patient was discharged from the intensive care unit to the general ward with severe volume overload, so intravenous furosemide was started. Central venous pressure assessment

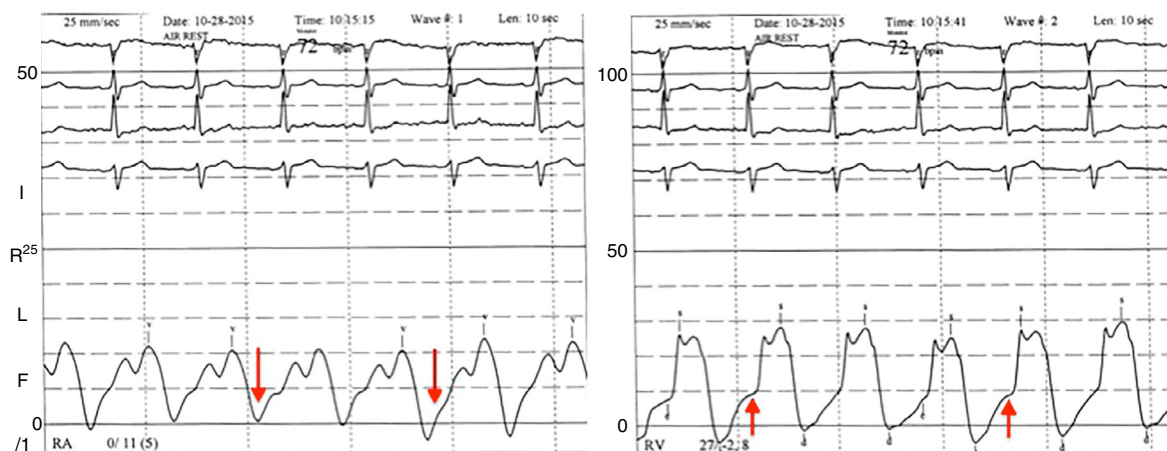


Figure 1 Right heart catheterization showing prominent v wave and abrupt y descent in right atrial pressure (left, red arrows) and a rapid increase in right ventricular pressure during early diastole (right, red arrows). RA: right atrium; RV: right ventricle.

* Corresponding author.
E-mail address: ortiz.bautista.carlos@gmail.com
(C. Ortiz-Bautista).

during orthostatism revealed a prominent v wave and abrupt y descent (Video 1). Two-dimensional echocardiography showed normal allograft function. Endomyocardial biopsy was performed by protocol and showed no evidence of cellular or humoral rejection. At the same time, right heart catheterization showed a prominent v wave and abrupt y descent in right atrial pressure (Figure 1, left, red arrows) and a rapid increase in right ventricular pressure during early diastole (Figure 1, right, red arrows), which confirmed the restrictive-constrictive physiology suspected from the physical examination.

A characteristic development of hemodynamics in heart and heart-lung transplants that mimics restrictive myocardial disease has been previously reported. Patients fulfill criteria for restrictive-constrictive physiology if they have increased diastolic pressure, an abrupt and rapid rise in pressure in early diastole, and rapid filling wave exceeding 4 mmHg. This hemodynamic pattern has been previously reported in patients with acute moderate cellular rejection. However, during the first weeks after heart transplantation, a restrictive-constrictive physiology may be present even in the absence of cellular rejection. This case shows that restrictive-constrictive physiology can be routinely assessed by physical examination.

Ethical disclosures

Protection of human and animal subjects. The authors declare that no experiments were performed on humans or animals for this study.

Confidentiality of data. The authors declare that no patient data appear in this article.

Right to privacy and informed consent. The authors declare that no patient data appear in this article.

Conflicts of interest

The authors have no conflicts of interest to declare.

Acknowledgments

Funding for this study was provided by Instituto de Salud Carlos III, Spanish Ministry of Economy and Competitiveness, through Red de Investigación Cardiovascular.

Appendix A. Supplementary material

Supplementary material associated with this article can be found in the online version at [doi:10.1016/j.repc.2016.07.017](https://doi.org/10.1016/j.repc.2016.07.017).