



ORIGINAL ARTICLE

# Importance of three-dimensional speckle tracking in the assessment of left atrial and ventricular dysfunction in patients with myotonic dystrophy type 1



Henrique Guedes<sup>a,\*</sup>, Nuno Moreno<sup>b</sup>, Rui Pontes dos Santos<sup>a</sup>, Leonor Marques<sup>a</sup>, Daniel Seabra<sup>a</sup>, Adriana Pereira<sup>a</sup>, Aurora Andrade<sup>a</sup>, Paula Pinto<sup>a</sup>

<sup>a</sup> Cardiology Department, Centro Hospitalar Tâmega e Sousa, Penafiel, Portugal

<sup>b</sup> Cardiology Department, Unidade Local de Saúde de Matosinhos, Hospital Pedro Hispano, Matosinhos, Portugal

Received 25 June 2017; accepted 28 October 2017

Available online 9 April 2018

## KEYWORDS

Myotonic dystrophy;  
Three-dimensional echocardiography;  
Three-dimensional speckle tracking;  
Strain

## Abstract

**Introduction and Aim:** Myotonic dystrophy type 1 (DM1) is a multisystem disease in which cardiac involvement is common. The aim of this study was to identify early changes in left atrial (LA) mechanics and left ventricular (LV) systolic function in patients with myotonic dystrophy type 1 using three-dimensional (3D) speckle tracking echocardiography (3D-STE).

**Methods:** This observational study included 25 patients with DM1 and 25 healthy volunteers. We assessed LA and LV global strain parameters using 3D-STE.

**Results:** Patients with DM1 showed significantly lower longitudinal LA strain ( $22.85\% \pm 5.06$  vs.  $26.82\% \pm 5.15$ ;  $p=0.008$  in univariate analysis and  $p=0.026$  in multivariate analysis) and global LV longitudinal strain ( $-13.55\% \pm 1.82$  vs.  $-16.11\% \pm 1.33$ ;  $p<0.001$  in univariate analysis and  $p<0.001$  in multivariate analysis), which was not observed with LA area tracking ( $p=0.412$ ) or LV global circumferential strain ( $p=0.879$ ), global radial strain ( $p=0.058$ ), area tracking ( $p=0.092$ ) or twist ( $p=0.992$ ).

**Conclusion:** LA and LV global longitudinal strain is significantly decreased in patients with DM1, which may be an early marker of subclinical dysfunction in these patients.

© 2018 Sociedade Portuguesa de Cardiologia. Published by Elsevier España, S.L.U. All rights reserved.

\* Corresponding author.

E-mail address: [henrique.jp.guedes@gmail.com](mailto:henrique.jp.guedes@gmail.com) (H. Guedes).

**PALAVRAS-CHAVE**

Distrofia miotónica;  
Ecocardiografia 3D;  
3D *speckle tracking*;  
*Strain*

## Importância da tecnologia 3D *speckle tracking* na avaliação da disfunção auricular e ventricular esquerda em doentes com distrofia miotónica do tipo 1

**Resumo**

**Introdução e objetivos:** A distrofia miotónica do tipo 1 é uma doença multissistémica com o envolvimento cardíaco a ser comum. O objetivo deste estudo foi identificar alterações precoces no *strain* da aurícula esquerda e função sistólica do ventrículo esquerdo em doentes com distrofia miotónica tipo 1, com o uso da tecnologia 3D *speckle tracking*.

**Métodos:** Estudo observacional, que incluiu 25 doentes com distrofia miotónica do tipo 1 e 25 voluntários saudáveis. Foram avaliados os parâmetros de deformação global da aurícula esquerda e do ventrículo com o uso de 3D *speckle tracking*.

**Resultados:** Os doentes com distrofia miotónica do tipo 1 apresentaram *strain* longitudinal da aurícula esquerda ( $22,85\% \pm 5,06$  versus  $26,82\% \pm 5,15$ ;  $p=0,008$  na análise univariada e  $p=0,026$  na análise multivariada) e *strain* global longitudinal do ventrículo esquerdo ( $-13,55\% \pm 1,82$  versus  $-16,11\% \pm 1,33$ ,  $p<0,001$  na análise univariada e  $p<0,001$  na análise multivariada) significativamente menores, o que não se verificou com a *area tracking* da aurícula esquerda ( $p=0,412$ ) ou com o *strain* global circunferencial ( $p=0,879$ ), *strain* global radial ( $p=0,058$ ), *area tracking* ( $p=0,092$ ) e *twist* ( $p=0,992$ ) do ventrículo esquerdo.

**Conclusão:** O *strain* longitudinal global do ventrículo esquerdo e da aurícula esquerda encontra-se significativamente diminuído em doentes com distrofia miotónica do tipo 1, pode ser um marcador precoce de disfunção subclínica nesaes doentes.

© 2018 Sociedade Portuguesa de Cardiologia. Publicado por Elsevier España, S.L.U. Todos os direitos reservados.

**List of abbreviations**

DM1	myotonic dystrophy type 1
LA	left atrial
LV	left ventricular
3D	three-dimensional
STE	speckle tracking echocardiography
2D	two-dimensional
LS	longitudinal strain
AT	area tracking
GLS	global longitudinal strain
GCS	global circumferential strain
GRS	global radial strain
ICC	intraclass correlation coefficient

**Introduction**

Myotonic dystrophy type 1 (DM1) is a multisystem neuromuscular disease with autosomal dominant transmission that affects smooth and skeletal muscle.<sup>1</sup> About 30% of mortality in adults with DM1 is due to cardiac involvement.<sup>2</sup> Arrhythmias, conduction system disturbances and myocardial fibrosis are the most frequent changes.<sup>3</sup> Detection of early markers may facilitate the identification of patients at risk of developing cardiac complications.

Left atrial (LA) function is a complex process that includes receiving pulmonary venous return during left ventricular (LV) systole, transfer of blood passively into the left

ventricle in early diastole, and active contraction in late diastole.<sup>4,5</sup>

In a comparison of volumetric real-time three-dimensional (3D) echocardiography and 3D speckle tracking echocardiography (3D-STE), the two methods were found to provide comparable and reproducible measurements, and to be interchangeable for quantification of LA dimensions and functional properties.<sup>6</sup>

Echocardiographic myocardial tracking systems using 3D-STE have provided new insights into ventricular function and atrial mechanics, with many potential clinical applications.<sup>7,8</sup> 3D formats more closely represent reality than two-dimensional (2D) formats, not only in the assessment of LV function but also in the diagnosis of valvular or myocardial disease. Determination of LV strain by 2D speckle tracking echocardiography (2D-STE) enables identification of changes in LV systolic function in patients with DM1.<sup>9,10</sup> However, the applicability of 3D-STE in these patients is not fully established and the available data are scarce.

The aim of this study was to identify early changes in LA mechanics and LV systolic function in patients with DM1 using 3D-STE.

**Methods****Study population**

This was a single-center observational study. After written informed consent was obtained, all 25 patients with DM1 followed in our center and 25 healthy volunteers (control group) were consecutively selected. All DM1 patients had genetic confirmation of the diagnosis and had no known

cardiovascular disease, but had signs of neuromuscular involvement (myopathic facies, myotonia or gait abnormalities).

### Echocardiographic protocol

The equipment used was an Artida™ scanner (Toshiba Medical Systems). The echocardiographic study began with a 2D echocardiogram following the standard protocol used in our department, measurements being made in accordance with the current guidelines of the American Society of Echocardiography,<sup>11</sup> using a PST-30SBT 1-5 MHz phased-array transducer.

For 3D echocardiography a PST-25SX 1-4 MHz phased-array matrix transducer was used. Images were acquired in apical 4-chamber and 2-chamber views for both LA and LV assessment. The data set is displayed in five planes: apical 4-chamber, apical 2-chamber, and three short-axis planes: apical region, middle segments and basal portion. The software is semiautomatic: it divides the left atrium and ventricle into 16 segments automatically, and after the markers have been selected, the system performs wall motion tracking analysis, enabling analysis of the study variables. The reference values for this equipment for 3D LV strain are: global longitudinal strain (GLS),  $-15.9\% \pm 2.4$ ; global circumferential strain (GCS),  $-30.6\% \pm 2.6$ ; global radial strain (GRS),  $35.6\% \pm 10.3$ ; area tracking (AT),  $-42\% \pm 2.4$ .<sup>12</sup>

### Variables analyzed

All patients were assessed for the presence of neuromuscular manifestations (particularly myotonia, muscular weakness and modified Rankin Scale [mRS] score) and of sleep, respiratory and gastrointestinal disorders, as established in the various consultations in which the patients were followed. Regarding electrocardiographic variables, rhythm, PR interval duration and QRS duration were recorded. On 2D echocardiography, LA size and volume, LV size and diastolic function and tricuspid annular plane systolic excursion (TAPSE) were determined, while LA emptying fraction and end-systolic and end-diastolic volumes and LV ejection fraction (LVEF), end-systolic and end-diastolic volumes and mass were determined by 3D echocardiography. LA deformation was determined by measuring longitudinal strain (LS) and AT, while LV deformation was determined by measuring GLS, GCS, GRS, AT and twist by 3D-STE (Figure 1).

### Interobserver and intraobserver variability

Data sets from the wall motion tracking results were analyzed at different times by two independent observers. The same images were also analyzed on different days by one of these observers. Blinding was ensured by analyzing the studies on different days by the same observer in a randomized order and by blinding the results between the two independent observers.

### Statistical analysis

Statistical analysis was carried out using SPSS version 22.0. Variables were analyzed for normality of distribution using the Kolmogorov-Smirnov test. Quantitative data are expressed as mean  $\pm$  SD and qualitative data as percentages. Comparisons were assessed using paired-samples *t* tests for quantitative data. Cox regression analysis was performed for multivariate adjustment. Correlations were assessed by simple linear regression analysis. Interobserver and intraobserver reproducibility were assessed by means of the intraclass correlation coefficient (ICC). Differences were considered statistically significant with a *p*-value  $< 0.05$ .

## Results

### Clinical and electrocardiographic data

Mean age was  $36.9 \pm 16.0$  years in DM1 patients ( $40.3 \pm 12.4$  years in controls). All patients had myotonia and 11 had muscle weakness, with a mean mRS of 1.25. Ten patients had PR interval  $> 200$  ms and seven had QRS  $> 120$  ms. Clinical and electrocardiographic data are displayed in Table 1.

### Echocardiographic data

Two-dimensional echocardiography did not identify differences between the groups in left cardiac chamber size or in parameters of diastolic function (Table 2).

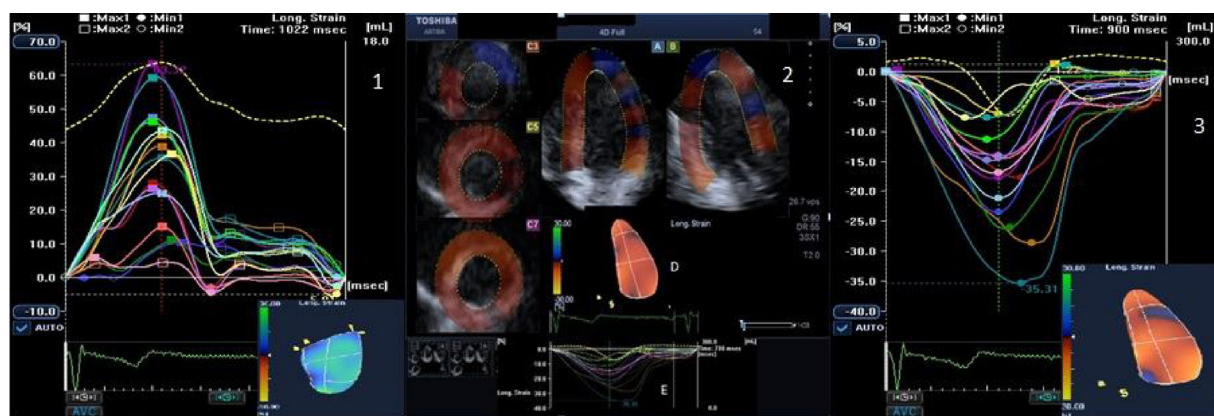
Also, three-dimensional echocardiography did not show significant differences in LVEF ( $62.88\% \pm 3.27$  vs.  $65.64\% \pm 6.65$ ,  $p=0.80$ ), LV mass index ( $91.83 \text{ g/m}^2 \pm 21.51$  vs.  $85.80 \text{ g/m}^2 \pm 15.73$ ,  $p=0.267$ ), LV end-systolic ( $24.42 \text{ ml/m}^2 \pm 12.54$  vs.  $25.16 \text{ ml/m}^2 \pm 9.87$ ,  $p=0.819$ ) or end-diastolic volume ( $55.85 \text{ ml/m}^2 \pm 23.14$  vs.  $54.53 \text{ ml/m}^2 \pm 15.05$ ,  $p=0.814$ ), or in LA emptying fraction ( $42.13\% \pm 8.53$  vs.  $46.37\% \pm 11.21$ ,  $p=0.139$ ) or indexed end-systolic ( $13.12 \text{ ml/m}^2 \pm 4.35$  vs.  $13.12 \text{ ml/m}^2 \pm 3.50$ ,  $p=0.569$ ) and end-diastolic volumes ( $22.70 \text{ ml/m}^2 \pm 4.75$  vs.  $23.60 \text{ ml/m}^2 \pm 6.19$ ,  $p=0.677$ ).

The percentage of segments analyzed with 3D-STE was 86.25%.

Patients with DM1 showed significantly lower LA LS than controls ( $22.85\% \pm 5.06$  vs.  $26.82\% \pm 5.15$ ;  $p=0.008$ ), which was not the case with AT ( $21.77\% \pm 17.49$  vs.  $25.41\% \pm 12.94$ ;  $p=0.412$ ). There was a significant correlation between age and LA LS in patients with DM1 ( $r=-0.771$ ;  $p<0.001$ ; Table 3).

LV GLS was significantly lower in patients with DM1 than in controls ( $-13.55\% \pm 1.82$  vs.  $-16.11\% \pm 1.33$ ;  $p<0.001$ ), which was not the case for GCS ( $-25.81\% \pm 7.57$  vs.  $-26.11\% \pm 5.92$ ;  $p=0.879$ ), GRS ( $26.36\% \pm 11.61$  vs.  $32.43\% \pm 10.50$ ;  $p=0.058$ ), AT ( $-35.58\% \pm 9.02$  vs.  $-39.27\% \pm 5.81$ ;  $p=0.092$ ) or twist ( $4.80 \pm 2.59$  vs.  $4.79 \pm 2.83$ ,  $p=0.992$ ). No correlation was found between PR interval ( $r=0.028$ ;  $p=0.906$ ), QRS ( $r=0.310$ ;  $p=0.183$ ) or 3D LV mass index ( $r=0.368$ ;  $p=0.077$ ) and LV GLS in DM1 patients (Table 3).

Multivariate adjustment confirmed that LA LS and LV GLS remained statistically significant ( $p=0.026$  and  $p<0.001$ , respectively).



**Figure 1** (1) LA LS (16 segments) obtained by means of 3D wall-motion tracking technology; during systole, the LA is stretched and LS increases, reaching a positive peak at the end of systole, corresponding to the end of atrial filling; during diastole, LS decreases to a plateau; (2) the 3D echocardiographic dataset is displayed in apical 4-chamber (A) and 2-chamber (B) views and three short-axis views in the basal (C3), mid-ventricular (C5), and superior (C7) regions, respectively. 3D LV cast (D) and GLS (E) are also presented; (3) LV GLS (16 segments) obtained by 3D wall-motion tracking technology. 3D: three-dimensional; GLS: global longitudinal strain; LA: left atrial; LS: longitudinal strain; LV: left ventricular.

**Table 1** Clinical and electrocardiographic data.

	DM1 patients	Controls	p
Age (years)	36.9±16.0	40.3±12.4	0.241
Female gender (%)	56	52	0.759
Sinus rhythm (n)	25	25	NA
PR interval (ms)	193±32	180±24	0.114
QRS (ms)	116±29	106±15	0.346
Myotonia (n)	25	N	NA
Muscle weakness (n)	11	N	NA
Mean mRS	1.25	N	NA
Sleep disorders (n)	2	N	NA
Respiratory disorders (n)	1	N	NA
Gastrointestinal disorders (n)	1	N	NA

Values are mean ± standard deviation.

DM1: myotonic dystrophy type 1; mRS: modified Rankin Scale score; N: normal; NA: not applicable.

Interobserver and intraobserver agreement for strain measurements was good. The ICCs are presented in Table 4

## Discussion

The assessment of myocardial deformation has been proposed as an early marker of subclinical dysfunction in DM1 patients.<sup>2</sup> The present study is, to our knowledge, the first to identify changes in both LA and LV strain measured by 3D-STE in these patients.

LA mechanics is considered an important clinical variable and its importance has been demonstrated in a number of conditions.<sup>13–19</sup> LA strain curves display the physiology of atrial function. The left atrium has four basic functions: phase 1, reservoir function (collection of pulmonary venous flow during LV systole); phase 2, conduit function (passage of blood to the left ventricle during early diastole); phase 3, active contractile pump function; and phase 4,

suction force.<sup>20</sup> During the reservoir phase, the left atrium is stretched, and consequently longitudinal atrial strain increases, reaching a positive peak at the end of atrial filling. After the atrium empties, LA strain decreases to a plateau, corresponding to LA diastasis, and then continues to decrease during the LA contraction phase (Figure 1).

In our study, a significant negative correlation was observed between age and LA LS in patients with DM1, which did not occur with the controls, suggesting a faster decrease in LA LS in these patients.

In DM1 patients, 2D-STE is able to identify changes in LS of the right atrium, which correlate with low-voltage areas on electrophysiological study.<sup>21</sup> However, LA mechanics has been little studied and validated in these patients, so it is difficult to draw definite conclusions about these findings. We expect that with future larger studies, these changes may prove to be important for early diagnosis and therapeutic decision-making.

Studies with 2D echocardiography are consistent in demonstrating decreased LV GLS in these patients,<sup>9,22</sup> as well as changes in GCS.<sup>9</sup> In our study, we found significant differences only in GLS, which may mean that these fibers are affected early in the progression of the disease, subsequently being replaced by fibrosis, as demonstrated in previous studies<sup>23</sup> and other cardiomyopathies, such as hypertrophic cardiomyopathy.<sup>24</sup> The presence of myocardial fibrosis in these patients has been documented by a cardiovascular magnetic resonance study,<sup>23</sup> in which myocardial fibrosis was found in 40% of patients and was not related to changes on electrocardiogram, Holter or echocardiogram. This suggests that assessment of myocardial fibrosis by cardiac magnetic resonance may be a useful tool in the assessment of these patients, since myocardial fibrosis may be the substrate for ventricular arrhythmias. Also, high levels of transforming growth factor beta 1, a sensitive marker of fibrosis, have been reported in patients with DM1, indicating a higher risk of arrhythmic events and sudden death.<sup>25</sup>

Previous studies have shown the usefulness of subclinical detection of cardiac involvement in DM1. In one study of



**Table 2** Two- and three-dimensional echocardiographic data.

	DM1 patients	Controls	p
<b>2D echocardiography</b>			
LA diameter (mm)	33.10±2.98	34.64±3.48	0.110
LAV/BSA (ml/m <sup>2</sup> )	23.68±5.22	26.77±6.09	0.070
LVEDD (mm)	45.12±4.94	47.53±3.99	0.064
IVS (mm)	8.96±1.34	9.68±1.52	0.082
PW (mm)	8.28±1.31	8.96±1.43	0.086
E/A	1.70±0.64	1.48±0.44	0.155
dT (ms)	197.36±47.89	172.84±41.90	0.058
E/E'	6.04±2.32	5.40±1.52	0.306
TAPSE (mm)	21.42±3.42	21.83±3.65	0.725
<b>3D echocardiography</b>			
LAEF (%)	42.13±8.53	46.37±11.21	0.139
LAESV/BSA (ml/m <sup>2</sup> )	13.12±4.35	13.12±3.50	0.569
LAEDV/BSA (ml/m <sup>2</sup> )	22.70±4.75	23.60±6.19	0.677
LA LS (%)	22.85±5.06	26.82±5.15	0.008
LA AT (%)	21.77±17.49	25.41±12.94	0.412
LVEF (%)	62.88±3.27	65.64±6.65	0.80
LV mass/BSA (g/m <sup>2</sup> )	91.83±21.51	85.80±15.73	0.267
LVESV/BSA (ml/m <sup>2</sup> )	24.42±12.54	25.16±9.87	0.819
LVEDV/BSA (ml/m <sup>2</sup> )	55.85±23.14	54.53±15.05	0.814
LV GLS (%)	-13.55±1.82	-16.11±1.33	<0.001
LV GCS (%)	-25.81±7.57	-26.11±5.92	0.879
LV GRS (%)	26.36±11.61	32.43±10.50	0.058
LV AT (%)	-35.58±9.02	-39.27±5.81	0.092
LV twist (°)	4.80±2.59	4.79±2.83	0.992
<b>Multivariate adjustment</b>			
LA LS	-	-	0.026
LV GLS	-	-	<0.001

Values are mean ± standard deviation.

2D: two-dimensional; 3D: three-dimensional; AT: area tracking; BSA: body surface area; DM1: myotonic dystrophy type 1; dT: deceleration time; GCS: global circumferential strain; GLS: global longitudinal strain; GRS: global radial strain; IVS: intra-ventricular septum; LA: left atrial; LAEF: left atrial emptying fraction; LAEDV: left atrial end-diastolic volume; LAESV: left atrial end-systolic volume; LS: longitudinal strain; LV: left ventricular; LVEDV: left ventricular end-diastolic volume; LVEF: left ventricular ejection fraction; LVESV: left ventricular end-systolic volume; PW: posterior wall; TAPSE: tricuspid annular plane systolic excursion.

**Table 3** Correlations in patients with myotonic dystrophy type 1.

	r	p
PR interval – LA LS	-0.304	0.192
Age – LA LS	-0.771	<0.001
PR interval – LV GLS	0.028	0.906
QRS – LV GLS	0.310	0.183
LV mass – LV GLS	0.368	0.077

GLS: global longitudinal strain; LA: left atrial; LS: longitudinal strain; LV: left ventricular; LV mass: left ventricular mass index on three-dimensional echocardiography.

**Table 4** Interobserver and intraobserver agreement.

	Intraobserver agreement	Interobserver agreement
LA LS	0.80	0.92
LA AT	0.89	0.83
LV GLS	0.95	0.91
LV GCS	0.83	0.90
LV GRS	0.90	0.89
LV AT	0.86	0.96
LV twist	0.87	0.91

Values are means of intraclass correlation coefficient.

AT: area tracking; GCS: global circumferential strain; GLS: global longitudinal strain; GRS: global radial strain; LA: left atrial; LV: left ventricular.

36 DM1 patients, serial Holter monitoring resulted in pacemaker implantation in 11 patients,<sup>26</sup> and implantable loop recorders have been used in small studies of asymptomatic patients, leading to the detection of ventricular arrhythmias and device implantation in four out of seven patients.<sup>27,28</sup> A recently published study demonstrated the prognostic value of LV GLS in patients with asymptomatic DM1, concluding that GLS constitutes a strong predictor of cardiovascular events.<sup>29</sup>

3D wall motion tracking uses a box template to detect speckle motion in 3D. The structures are captured in a full volume and do not move out of plane like in 2D. 3D-STE has also been shown to provide a faster and more complete assessment than 2D-STE, overcoming some of the shortcomings of previous techniques by reducing the intraobserver and interobserver variability inherent in 2D measures and avoiding the angle dependence of strain and strain-rate measures obtained on Doppler tissue imaging.<sup>7</sup> Nesser et al.<sup>30</sup> assessed the accuracy of measuring LV volumes by means of 3D-STE side by side with 2D-STE using cardiac magnetic resonance as a reference. They observed that measurements by 3D-STE showed higher correlation with cardiac magnetic resonance, smaller biases and narrower limits of agreement. 3D-STE is emerging as a useful tool for a more comprehensive assessment of ventricular function and atrial mechanics and may be valuable in a general and systematic approach to these patients, bearing in mind its possible prognostic impact.

This study has some limitations. One is the small number of patients (total 25), which is in line with the rarity of the disease (estimated prevalence of about 1/10 000) and previous studies performed in patients with this condition. It also has the inherent limitations of an observational study and, as pointed out above, the clinical impact of LA deformation changes are still not well understood. Regarding image acquisition, a major limitation for current 3D-STE systems is their relatively low temporal resolution, with typical frame rates of 20-25 volumes/s, and sequential volume acquisition, which is vulnerable to motion artifacts if the patient is unable to cooperate. The software used continues to improve but is not fully validated for the study of the left atrium.

## Conclusion

LA LS and LV GLS are significantly decreased in patients with DM1. These results may reflect a subclinical and early marker of myocardial dysfunction in these patients. Studies with 3D-STE can detect changes in myocardial function that may contribute to the assessment and follow-up of these patients. Future prospective studies may open new perspectives on the clinical relevance of these markers.

## Conflicts of interest

The authors have no conflicts of interest to declare.

## Acknowledgment

The authors are grateful to Leopoldo Pérez de Isla, MD, and Fabián Islas, MD, both from the Cardiology Department, Hospital Clínico San Carlos, Madrid, Spain.

## References

- Harper PS. *Myotonic dystrophy*. 3rd ed. London: Saunders; 2001.
- Lau JK, Sy RW, Corbett A, et al. Myotonic dystrophy and the heart: a systematic review of evaluation and management. *Int J Cardiol*. 2015;184:600–8.
- Petri H, Vissing J, Witting N, et al. Cardiac manifestations of myotonic dystrophy type 1. *Int J Cardiol*. 2012;160:82–8.
- Piros GA, Domsika P, Kalapos A, et al. Left atrial ejection force correlates with left atrial strain and volume-based functional properties as assessed by three-dimensional speckle tracking echocardiography (from the MAGYAR-Healthy Study). *Rev Port Cardiol*. 2016;35:83–91.
- Todaro MC, Choudhuri I, Belohlavek M, et al. New echocardiographic techniques for evaluation of left atrial mechanics. *Eur Heart J Cardiovasc Imaging*. 2012;13:973–84.
- Kleijn SA, Aly MF, Terwee CB, et al. Comparison between direct volumetric and speckle tracking methodologies for left ventricular and left atrial chamber quantification by three-dimensional echocardiography. *Am J Cardiol*. 2011;108:1038–44.
- Isla LP, Balcones DV, Fernández-Golfín C, et al. Three-dimensional-wall motion tracking: a new and faster tool for myocardial strain assessment: comparison with two-dimensional-wall motion tracking. *J Am Soc Echocardiogr*. 2009;22:325–30.
- Gorcsan J, Tanaka H. Are new myocardial tracking systems of three-dimensional strain a reality in daily clinical practice? *Rev Esp Cardiol*. 2011;64:1082–9.
- Wahbi K, Ederhy S, Bécane HM, et al. Impaired myocardial deformation detected by speckle-tracking echocardiography in patients with myotonic dystrophy type 1. *Int J Cardiol*. 2011;152:375–6.
- Petri H, Witting N, Ersboll MK, et al. High prevalence of cardiac involvement in patients with myotonic dystrophy type 1: a cross-sectional study. *Int J Cardiol*. 2014;174:31–6.
- Lang RM, Badano LP, Mor-Avi V, et al. Recommendations for cardiac chamber quantification by echocardiography in adults: an update from the American Society of Echocardiography and the European Association of Cardiovascular Imaging. *J Am Soc Echocardiogr*. 2015;28:1–39.
- Kleijn SA, Pandian NG, Thomas JD, et al. Normal reference values of left ventricular strain using three-dimensional speckle tracking echocardiography: results from a multicentre study. *Eur Heart J Cardiovasc Imaging*. 2015 Apr;16:410–6.
- Islas F, Olmos C, Vieira C, et al. Thromboembolic risk in atrial fibrillation: association between left atrium mechanics and risk scores. A study based on 3D wall-motion tracking technology. *Echocardiography*. 2015;32:644–53.
- Cameli M, Lisi M, Mondillo S, et al. Left atrial longitudinal strain by speckle tracking echocardiography correlates well with left ventricular filling pressures in patients with heart failure. *Cardiovasc Ultrasound*. 2010;8:14.
- Cameli M, Lisi M, Giacomini E, et al. Chronic mitral regurgitation: left atrial deformation analysis by two-dimensional speckle tracking echocardiography. *Echocardiography*. 2011;28:327–34.
- O'Connor K, Magne J, Rosca M, et al. Left atrial function and remodelling in aortic stenosis. *Eur J Echocardiogr*. 2011;12:299–305.
- Antoni ML, ten Brinke EA, Atary JZ, et al. Left atrial strain is related to adverse events in patients after acute myocardial infarction treated with primary percutaneous coronary intervention. *Heart*. 2011;97:1332–7.
- Telagh R, Hui W, Abd El Rahman M, et al. Assessment of regional atrial function in patients with hypertrophic cardiomyopathies using tissue Doppler imaging. *Pediatr Cardiol*. 2008;29:301–8.
- D'Andrea A, De Corato G, Scarafilo R, et al. Left atrial myocardial function in either physiological or pathological left ventricular hypertrophy: a two-dimensional speckle strain study. *Br J Sports Med*. 2008;42:696–702.
- Vieira MJ, Teixeira R, Gonçalves L, et al. Left atrial mechanics: echocardiographic assessment and clinical implications. *J Am Soc Echocardiogr*. 2014;27:463–78.
- Ballo P, Giaccardi M, Colella A, et al. Mechanical and electrophysiological substrate for recurrent atrial flutter detected by right atrial speckle tracking echocardiography and electroanatomic mapping in myotonic dystrophy type 1. *Circulation*. 2013;127:1422–4.
- Wissocque L, Brigadeau F, Richardson M, et al. Impairment of global and regional longitudinal strains in patients with myotonic dystrophy type 1. *Int J Cardiol*. 2015;191:46–7.
- Petri H, Ahtarovski KA, Vejlstrop N, et al. Myocardial fibrosis in patients with myotonic dystrophy type 1: a cardiovascular magnetic resonance study. *J Cardiovasc Magn Reson*. 2014;16:59.
- Afonso L, Kondur A, Simegn M, et al. Two-dimensional strain profiles in patients with physiological and pathological hypertrophy and preserved left ventricular systolic function: a comparative analyses. *BMJ Open*. 2012;0:e001390.
- Turillazzi E, Neri M, Riezzo I, et al. Cardiac fibrosis, arrhythmia and sudden death in myotonic dystrophy type 1: could TGF- $\beta$ 1 improve the predictive accuracy of patients at risk, opening new therapeutic challenges? *Int J Cardiol*. 2013;168:4976–8.
- Sa MI, Cabral S, Costa PD, et al. Ambulatory electrocardiographic monitoring in type 1 myotonic dystrophy. *Rev Port Cardiol*. 2007;26:745–53.
- Stollberger C, Steger C, Gabriel P, et al. Implantable loop recorders in myotonic dystrophy 1. *Int J Cardiol*. 2011;152:249–51.
- Hadian D, Lowe MR, Scott LR, et al. Use of an insertable loop recorder in a myotonic dystrophy patient. *J Cardiovasc Electrophysiol*. 2002;13:72–3.
- Garcia R, Rehman M, Goujeau C, et al. Left ventricular longitudinal strain impairment predicts cardiovascular events in asymptomatic type 1 myotonic dystrophy. *Int J Cardiol*. 2017;243:424–30.
- Nesser HJ, Mor-Avi V, Gorissen W, et al. Quantification of left ventricular volumes using three-dimensional echocardiographic speckle tracking: comparison with MRI. *Eur Heart J*. 2009;30:1565–73.