



CASE REPORT

Percutaneous closure of iatrogenic femoral arteriovenous fistula using a covered coronary stent



Juan Carlos Rama-Merchan, Ignacio Cruz-González*, Javier Martín-Moreiras, Alejandro Diego-Nieto, Javier Rodríguez-Collado, Pedro Luis Sánchez

Department of Cardiology, University Hospital of Cardiology & IBSAL, Salamanca, Spain

Received 20 January 2016; accepted 12 May 2016
Available online 27 February 2017

KEYWORDS

Left atrial appendage;
Arteriovenous fistula;
Covered coronary stent

Abstract We present the case of a patient with a high-output fistula between the right superficial femoral artery and femoral vein after left atrial appendage closure successfully treated with a PK-Papyrus covered coronary stent using a 6F guiding catheter. To the best of our knowledge this is the first time a PK-Papyrus coronary stent has been used in this setting.
© 2017 Sociedade Portuguesa de Cardiologia. Published by Elsevier España, S.L.U. All rights reserved.

PALAVRAS-CHAVE

Apêndice atrial esquerdo;
Fístula arteriovenosa;
Stent coronário recoberto

Oclusão percutânea de fístula arteriovenosa femoral iatrogénica usando *stent* coronário recoberto

Resumo Apresentamos o caso de um paciente com uma fístula de alto débito entre a artéria femoral superficial direita e a veia femoral, depois de uma oclusão do apêndice atrial esquerdo, tratada com êxito com um *stent* coronário recoberto PK-PAPYRUS usando um cateter 6 F. Até onde sabemos, esta é a primeira vez que o PK-PAPYRUS é o usado neste contexto.
© 2017 Sociedade Portuguesa de Cardiologia. Publicado por Elsevier España, S.L.U. Todos os direitos reservados.

Introduction

Percutaneous left atrial appendage (LAA) closure devices have been developed as a non-pharmacologic alternative to oral anticoagulant (OAC) therapy for stroke prevention in patients with non-valvular atrial fibrillation (NVAF).¹ Vascular access site complications following percutaneous LAA

* Corresponding author.
E-mail address: cruzgonzalez.ignacio@gmail.com
(I. Cruz-González).

closure are infrequent,^{2,3} but may be associated with serious consequences.

We present the case of a patient with a high-output fistula between the right superficial femoral artery and femoral vein after LAA closure successfully treated with a PK-Papyrus covered coronary stent using a 6F guiding catheter. To the best of our knowledge this is the first time a PK-Papyrus coronary stent has been used in this setting.

Case report

An 86-year-old female patient with NVAf, high risk of stroke (CHA₂DS₂-VAsC score of 5) and contraindication to OAC therapy (previous hemorrhagic stroke), underwent percutaneous closure of the LAA with an Amulet device (AGA/St. Jude Medical, Minneapolis, MN). The procedure was performed under general anesthesia, with fluoroscopic and two- and three-dimensional transthoracic echocardiographic guidance. The right femoral vein was cannulated using the Seldinger technique and a transseptal puncture was performed with a Mullins sheath and Brockenbrough needle. A 20 mm Amulet occluder device was successfully deployed (Figure 1).

At the end of the procedure after manual compression, prolonged pulsatile bleeding by the femoral venous access was observed. A control angiography obtained from the contralateral (left) femoral artery revealed a high-output fistula between the right superficial femoral artery and

femoral vein (Figure 2A). After discussion with the vascular team the decision was made to implant a covered stent. A 26 mm×4.5 mm PK-Papyrus covered coronary stent (Biotronik, Bülach, Switzerland) was inserted via the left femoral artery and deployed at the arteriovenous (AV) fistula using a 6F multipurpose catheter (Cordis Corporation) and a coronary guidewire (Balanced Heavyweight, Abbott Vascular Inc.). At final angiography, complete sealing of the AV fistula was documented (Figure 2B).

The patient was discharged after 48 hours without complications. Six months after the procedure, she was asymptomatic and Doppler ultrasonography of the right femoral segment was normal.

Discussion

Percutaneous LAA closure is a demonstrated alternative strategy to OAC therapy for stroke prophylaxis in patients with NVAf.¹ Vascular access site complications (perforations, pseudoaneurysms or AV fistulas) following percutaneous LAA closure are infrequent,^{2,3} but require immediate assessment and management and may be associated with adverse outcomes.

These vascular complications can be treated percutaneously using covered stents with high technical success, thus avoiding high-risk urgent vascular surgery.⁴⁻⁶ To the best of our knowledge this is the first time a PK-Papyrus coronary stent has been used in this setting.

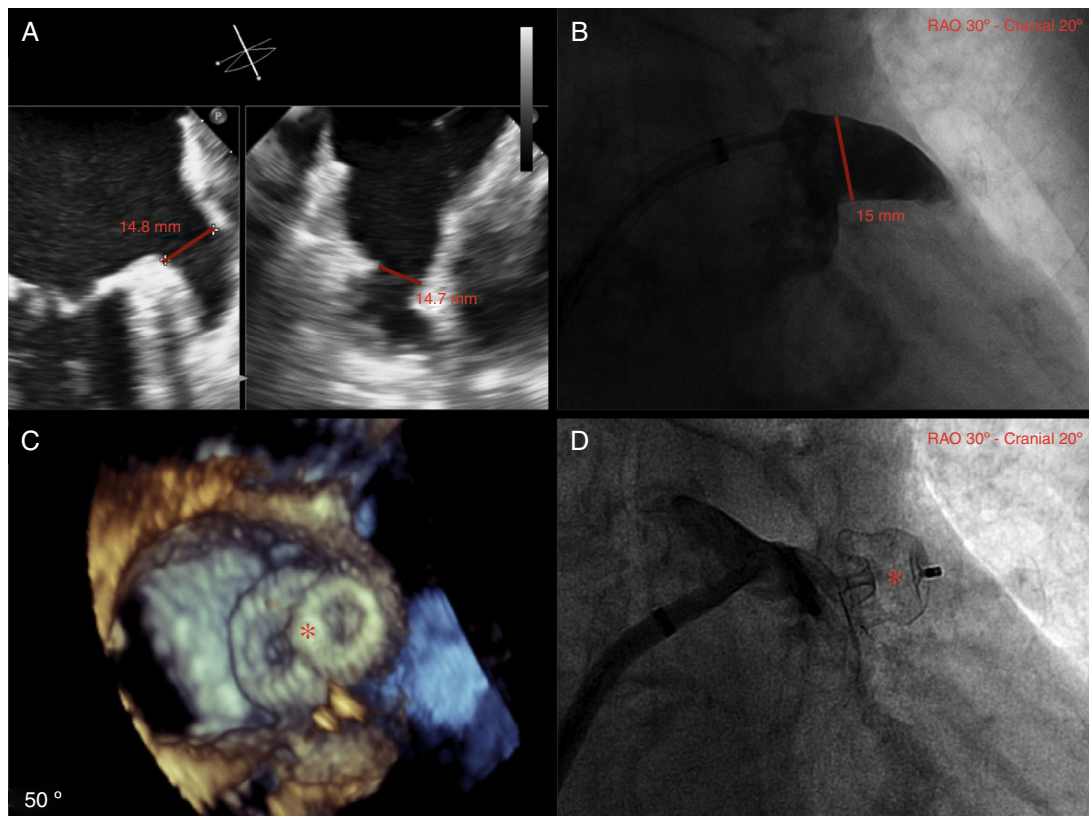


Figure 1 (A) Left atrial appendage (LAA) size by biplane two-dimensional transthoracic echocardiography (TEE); (B) LAA size by angiography (windsock morphology); (C) three-dimensional TEE showing complete occlusion of the LAA with the Amulet device (red asterisk); (D) angiography showing complete occlusion of the LAA with the Amulet device (red asterisk).

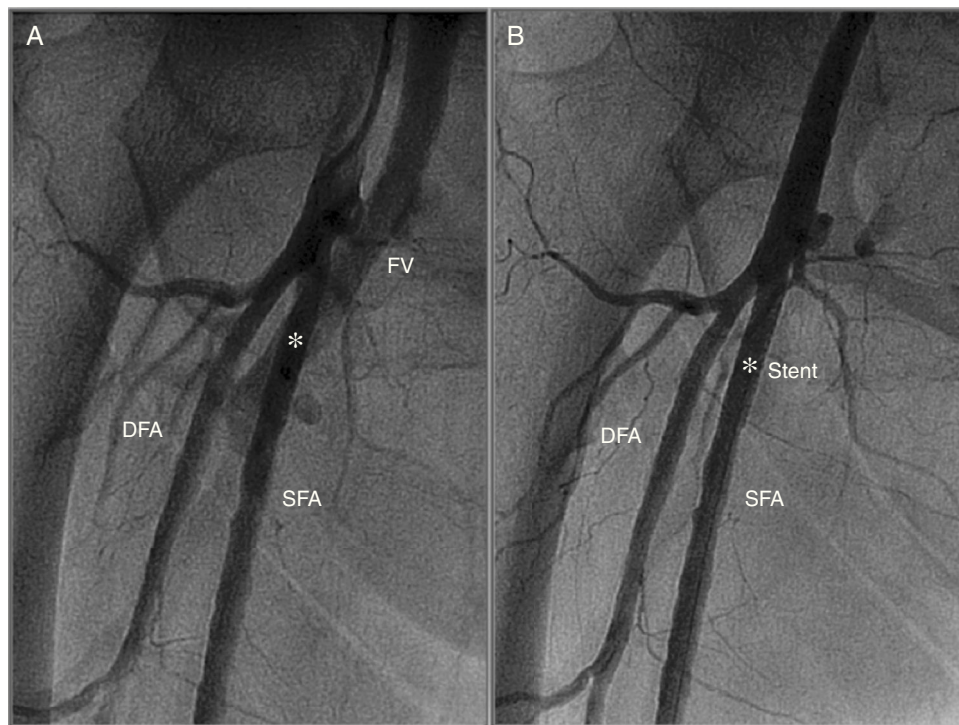


Figure 2 (A) Angiography obtained from the contralateral femoral artery (left) revealing a high-output arteriovenous fistula between the right superficial femoral artery and femoral vein (white asterisk); (B) angiography after implantation of a 26 mm×4.5 mm PK-Papyrus covered coronary stent (white asterisk) revealing complete sealing of the AV fistula. DFA: deep femoral artery; FV: femoral vein; SFA: superficial femoral artery.

The PK-Papyrus covered coronary stent is a sixth-generation bare-metal stent made of a cobalt-chromium alloy, which allows for thinner struts while still maintaining optimal radial strength and radiopacity. The polyurethane membrane covering the stent is only 90 μ m thick. The wide size range (diameter 2.5-5.0 mm, length 15-26 mm) enables a broad range of vessels to be treated confidently and efficiently. Many current covered stents designed for peripheral interventions require large guiding catheters to be deployed. The PK-Papyrus stent is compatible with 5F- and 6F-guiding catheters (recommended sizes are 5F for 2.5-4.0 mm stents and 6F for 4.5-5.0 mm stents), and thus may reduce vascular complications related to the large (>6F) catheters and sheaths frequently used in these interventions. In addition, the techniques and materials used for the implantation of a PK-Papyrus covered stent in a peripheral segment are the same as used in coronary interventions.

Conclusion

AV fistulas following percutaneous LAA closure are infrequent, but may be associated with adverse outcomes. The PK-Papyrus covered coronary stent can be a good choice for percutaneous treatment of these complications.

Ethical disclosures

Protection of human and animal subjects. The authors declare that no experiments were performed on humans or animals for this study.

Confidentiality of data. The authors declare that they have followed the protocols of their work center on the publication of patient data and that all the patients included in the study received sufficient information and gave their written informed consent to participate in the study.

Right to privacy and informed consent. The authors have obtained the written informed consent of the patients or subjects mentioned in the article. The corresponding author is in possession of this document.

Conflicts of interest

The authors have no conflicts of interest to declare.

References

1. Holmes DR, Reddy VY, Turi ZG, et al. Percutaneous closure of the left atrial appendage versus warfarin therapy for prevention of stroke in patients with atrial fibrillation: a randomised non-inferiority trial. *Lancet*. 2009;374:534–42.
2. Reddy VY, Holmes D, Doshi SK, et al. Safety of percutaneous left atrial appendage closure: results from the Watchman Left Atrial Appendage System for Embolic Protection in Patients with AF (PROTECT AF) clinical trial and the Continued Access Registry. *Circulation*. 2011;123:417–24.
3. Holmes DR Jr, Kar S, Price MJ, et al. Prospective randomized evaluation of the Watchman Left Atrial Appendage Closure device in patients with atrial fibrillation versus long-term

- warfarin therapy: the PREVAIL trial. *J Am Coll Cardiol*. 2014;64:1–12.
4. Thalhammer C, Kirchherr AS, Uhlich F, et al. Postcatheterization pseudoaneurysms and arteriovenous fistulas: repair with percutaneous implantation of endovascular covered stents. *Radiology*. 2000;214:127–31.
 5. Onal B, Kosar S, Gumus T, et al. Postcatheterization femoral arteriovenous fistulas: endovascular treatment with stent-grafts. *Cardiovasc Intervent Radiol*. 2004;27:453–8.
 6. Kufner S, Cassese S, Groha P, et al. Covered stents for endovascular repair of iatrogenic injuries of iliac and femoral arteries. *Cardiovasc Revasc Med*. 2015;16:156–62.