



## Case Report

# Temporary aneurysm neck balloon occlusion during percutaneous thrombin embolization of a superficial femoral artery pseudoaneurysm



Joana Ferreira<sup>a,\*</sup>, Pedro Sousa<sup>b</sup>

<sup>a</sup> Vascular Surgery, Hospital da Senhora da Oliveira, Guimarães/EPE, Portugal

<sup>b</sup> Radiology, Centro Hospitalar de Trás-os-Montes e Alto Douro/EPE, Portugal

## ARTICLE INFO

### Article history:

Received 23 October 2016

Accepted 5 December 2016

Available online 28 December 2016

### Keywords:

Pseudoaneurysm

Thrombin

Neck occlusion

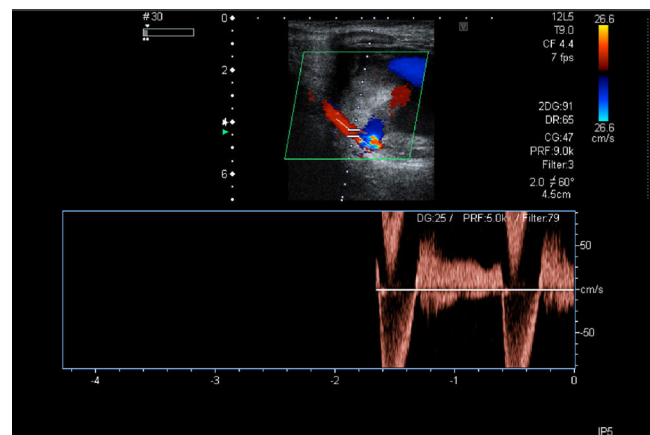
## ABSTRACT

An iatrogenic pseudoaneurysm of the superficial femoral artery was embolized with ultrasonographically guided thrombin injection. In order to avoid thrombin migration to the limb arteries, during the injection, the aneurysm neck was temporarily occluded, inflating a 5 mm balloon. The balloon was deployed endovascularly with a crossover technique. At six months' follow-up, the pseudoaneurysm remained occluded and the limb arteries were patent.

© 2016 PBJ-Associação Porto Biomedical/Porto Biomedical Society. Published by Elsevier España, S.L.U. This is an open access article under the CC BY-NC-ND license (<http://creativecommons.org/licenses/by-nc-nd/4.0/>).

## Case report

A 79-year-old female was admitted with a pulsating mass in the right thigh. Three months before, a temporary haemodialysis catheter had been inserted in the right common femoral vein. She underwent a Doppler ultrasound which showed a right superficial femoral artery pseudoaneurysm measuring 6 cm × 5 cm with a 5 mm × 5 mm × 1 mm neck (Fig. 1). In order to plan the pseudoaneurysm correction a CT scan was performed (Fig. 2). We decided to correct the aneurysm with thrombin injection, while the aneurysm neck was occluded with a balloon. The left common femoral artery was punctured. Using a crossover technique, a 5 mm balloon was displaced at the right superficial femoral artery, near to the pseudoaneurysm neck. Percutaneous ultrasonographically guided thrombin injection was performed under real time color Doppler ultrasound monitoring. During the thrombin injection the balloon was inflated to occlude the aneurysm neck (20 min in each thrombin injection) (Fig. 3). Injection was performed as far away as possible from the pseudoaneurysm neck. There were no complications and the pseudoaneurysm was excluded. Doppler ultrasound performed six months after the treatment, showed no blood flow in the aneurysm sac and the superficial femoral artery was patent (Fig. 4). The distal right limb pulses were present.



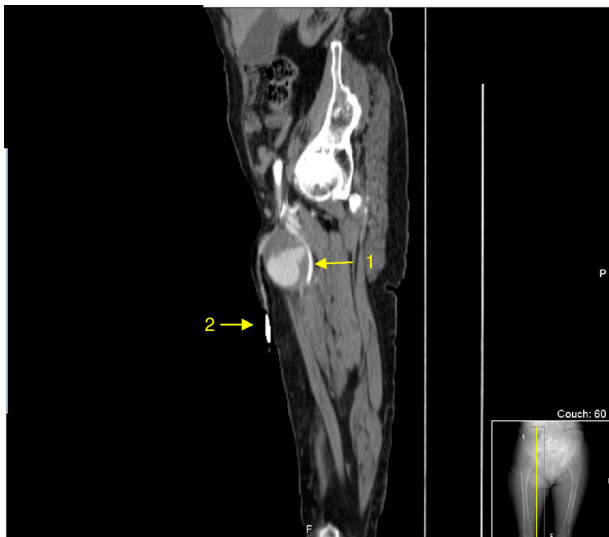
**Fig. 1.** Doppler ultrasound of the right superficial femoral artery pseudoaneurysm. A typical “to-and-fro” waveform in the neck of the pseudoaneurysm is shown.

## Discussion

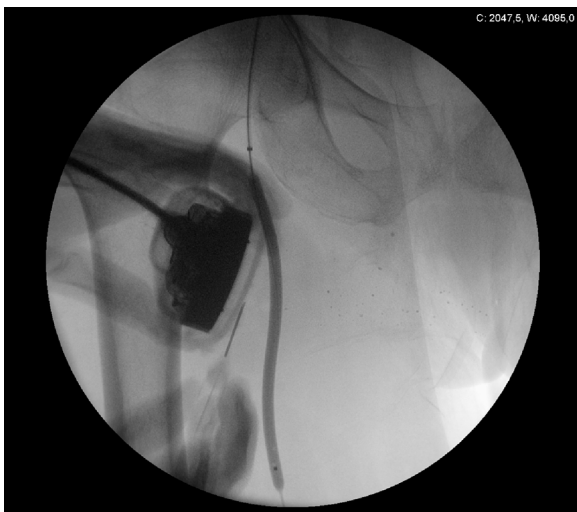
Pseudoaneurysms are frequently iatrogenic. The pseudoaneurysms can cause skin necrosis, neuropathy, deep venous thrombosis and can rupture.<sup>1</sup> They should be excluded to avoid these complications. They can be treated with ultrasound-guided compression, surgical intervention, stent implantation or with percutaneous thrombin injection.<sup>2,3</sup> Due to its minimally invasiveness, percutaneous thrombin is an appealing option.<sup>2</sup> However, in

\* Corresponding author.

E-mail address: [joana222@hotmail.com](mailto:joana222@hotmail.com) (J. Ferreira).

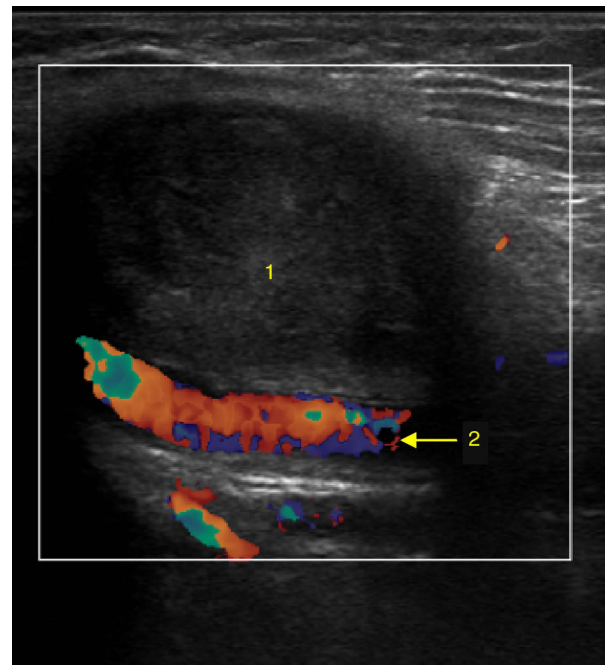


**Fig. 2.** CTA showing the pseudoaneurysm of the right superficial femoral artery (1). It is possible to identify the haemodialysis catheter in the common femoral vein (2).



**Fig. 3.** Angiography showing percutaneous ultrasonographically guided thrombin injection under real time color Doppler ultrasound monitoring. The balloon is inflated during thrombin injection.

pseudoaneurysm with short and large neck there is a risk of thrombin embolization to the nearby artery.<sup>3</sup> In the case report described, thrombin embolization could cause acute limb ischemia. To minimize this risk, during the thrombin injection, the pseudoaneurysm



**Fig. 4.** Doppler ultrasound six months after pseudoaneurysm correction. There is no blood flow in the aneurysm sac (1). The superficial femoral artery is patent (2) and distal right limb pulse is present.

neck was temporarily occluded with a balloon. In the case reported this was a valuable option.

#### Conflicts of interest

The authors declare no conflicts of interest.

#### References

1. Kuma S, Morisaki K, Kodama A, Guntani A, Fukunaga R, Soga Y, et al. Ultrasound-guided percutaneous thrombin injection for post-catheterization pseudoaneurysm. *Circ J.* 2015;79:1277–81, <http://dx.doi.org/10.1253/circj.CJ-14-1119>.
2. Bydawell G. Percutaneous thrombin injection for pseudoaneurysm treatment. *S Afr J Rad.* 2013;17:41–2, <http://dx.doi.org/10.7196/SAJR.792>.
3. Lorenz E, Herold J, Udelnow A, Pech M, Halloul Z. Percutaneous thrombin embolization of an iatrogenic pseudoaneurysm of the subclavian artery with neuroprotection in a critically ill patient. *Vasa.* 2015;44:391–4, <http://dx.doi.org/10.1024/03011526/a000459>.